

A. GANGI MD, PHD, S. GUTH MD, J-L. DIETEMANN MD, C. ROY MD.

Department of Radiology, University Louis Pasteur Strasbourg (Cum Laude RSNA 2000)

Any questions or to submit cases please send us the mail at following addresses

E-mail : Afshin Gangi - E-mail : Stephane Guth

Scientific work : A. GANGI MD, PHD, S. GUTH MD, Geoff Hide MD, J-L. DIETEMANN MD, C. ROY MD.

Web design, HTML and JAVA program : S. GUTH MD

A special note of gratitude goes to Stephen Ferron, Petra Gangi and Nathalie Chalus for checking the presentation.

Copyright © 2001: Guth S. Gangi A.

## 1) Introduction

Percutaneous Cementoplasty (PC, vertebral packing, vertebroplasty) with acrylic glue (polymethylmethacrylate: PMMA) is a procedure aimed at preventing vertebral body collapse and pain in patients with pathological vertebral bodies. Percutaneous cementoplasty is a promising therapeutic technique for pain control in patients with bone failure.

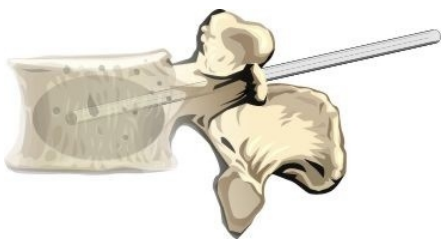

Fig 1: principle

## 2) Principle

The analgesic effect of cement cannot be explained by the consolidation of the pathological bone alone. In fact, good pain relief is obtained after injection of only 2 ml of methyl methacrylate in metastasis. In these cases the consolidation effect is minimal. The methyl methacrylate is cytotoxic due to its chemical and thermal effect during polymerization. The temperature during polymerization is high enough to produce coagulation of the tumoral cells. Therefore, good pain relief can be obtained with a low volume of glue.

## 3) Indications

Percutaneous injection of acrylic glue is indicated in cases of :

- Symptomatic vertebral angioma.
- Painful vertebral body tumors (particularly metastasis and myeloma). The best indications are painful vertebral body tumors, when there is a risk of compression fracture.
- Severe painful osteoporosis with loss of height and/or with compression fractures of the vertebral body.

## 4) Contraindications

- Hemorrhagic diathesis
- Infection
- Lesions with epidural extension require careful injection to prevent epidural overflow and spinal cord compression by the cement or displaced epidural tissue.

## 5) Technique

### overview

The procedure is performed under local anesthesia usually combined with neuroleptanalgesia. The patient is placed in the prone position for lumbar and thoracic level and in the supine position for cervical level. A 15-gauge needle is used for cervical vertebral bodies, a 10-gauge needle for thoracic and lumbar vertebrae. We always use dual guidance : CT and C-arm fluoroscopy. The entry point and the pathway are determined by CT, avoiding the nerve root and visceral structures. The needle is safely guided under CT.

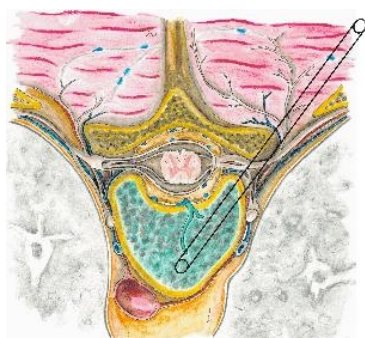


Fig 2 : PC axial plane

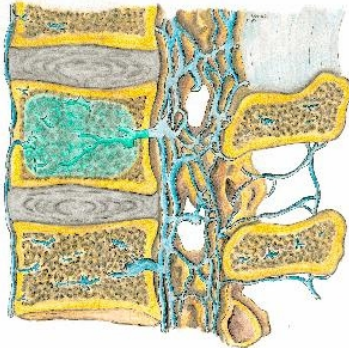


Fig 3: PC sagittal plane

Once the needle is in the optimal position, the imaging mode is switched to fluoroscopy. The acrylic cement mixed with tantalum (to increase radio-opacity) has to be injected during its pasty polymerization phase to prevent distal venous migration. The injection of glue is carefully controlled under strict lateral fluoroscopy. The injection of glue is stopped whenever an epidural or paravertebral opacification is observed or when the glue reaches the posterior quarter of the vertebral body.

## Material

- 10-gauge vertebroplasty bevelled needle (Optimed®) for thoracic and lumbar spine and a 15-gauge needle for cervical spine
- Surgical hammer
- Acrylic glue (methyl methacrylate Howmedica®, Microlok®, Simplex® or Palacos® low viscosity)
- Pressure syringe (Optimed®) to facilitate the injection of this viscous glue
- and 3g tantalum or tungsten (acrylic cement is not sufficiently radio-opaque)
- Sterile drapes, towels
- 22-gauge needle for anesthesia, scalpel
- Iodine, 1% lidocaine



Fig 4: PC pressure syringe, 10-g needle

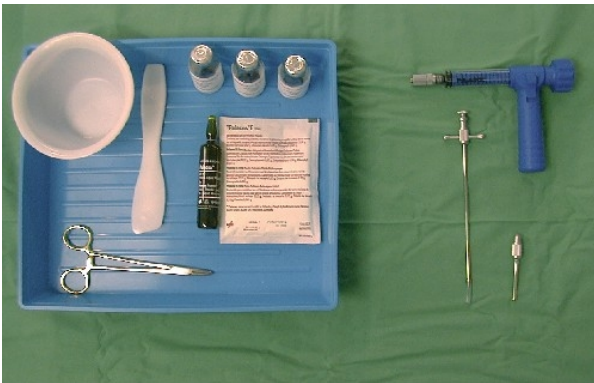


Fig 5a: PC material acrylic glue, pressure syringe, 3g tantalum, 10-g needle

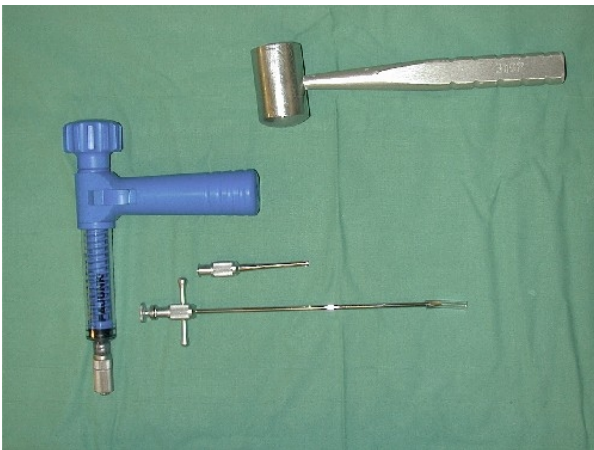


Fig 5b: PC material surgical hammer, pressure syringe, 10-g needle

## Dual guidance

Percutaneous cementoplasty, like other interventional procedures, is usually performed with a single imaging technique : fluoroscopy or CT, both of which have advantages and drawbacks. Fluoroscopy offers multiple planes and direct imaging with the disadvantages of poor soft-tissue contrast and non-negligible radiation exposure for both patient and operator. CT is well-suited for precise interventional needle guidance because it provides good visualization of both bone and surrounding soft tissues. It also avoids damage to adjacent vascular, neurological, and visceral structures. The disadvantages of are restriction to the axial plane and delayed imaging.

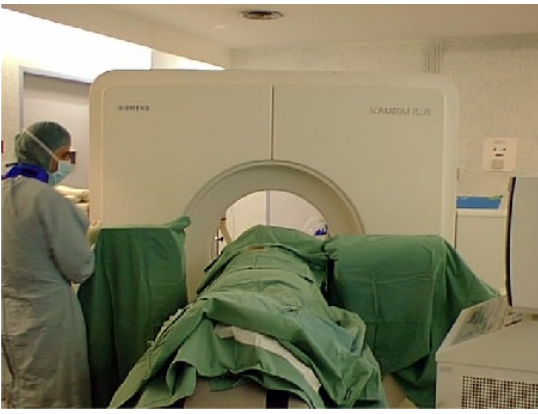

Fig 6: dual guidance CT and fluoroscopy

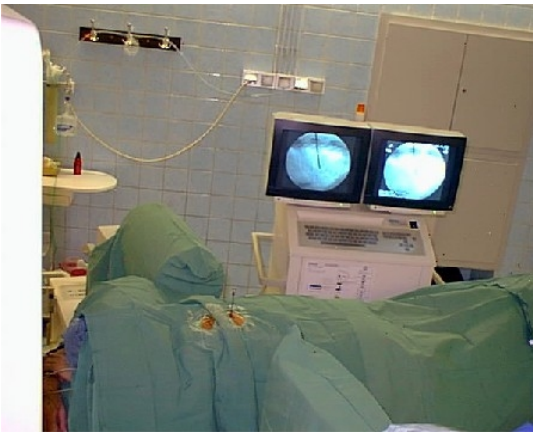

Fig 7: dual guidance fluoroscopy and CT

To address these concerns on a routine basis, a combination of CT and fluoroscopy for interventional procedures has been recommended. For fluoroscopy, a mobile C-arm is used, positioned in front of the CT-gantry. By using a rotating fluoroscope and CT, the structure to be punctured can be visualized three dimensionally and with exact differentiation of anatomic structures, which in many cases is not possible with fluoroscopy alone. Two mobile monitors are placed in front of the physician, displaying the last stored image and the fluoroscopic image. The operator can switch from CT to fluoroscopy and vice versa at any time as shown in the dual guidance movie.

(go to movie [page](#))

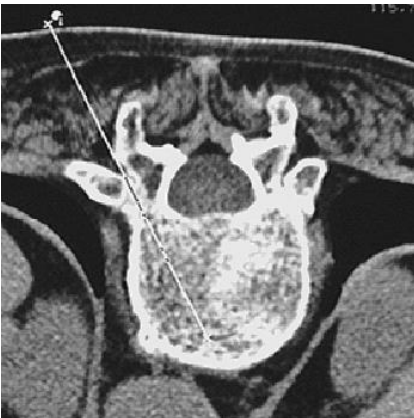


Fig 8: CT pathway

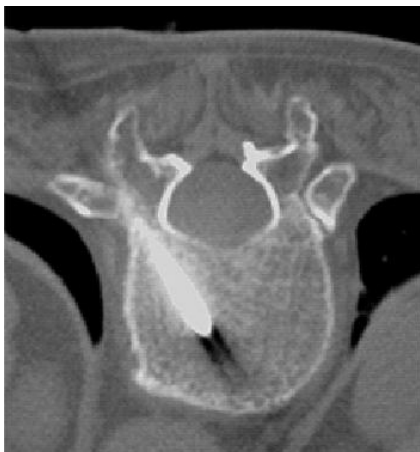

Fig 9: CT control

In percutaneous vertebroplasty, the intervention begins with CT and is followed by fluoroscopy. The needle is placed precisely and safely under CT guidance. The injection of the methyl methacrylate requires real-time imaging and is therefore performed under fluoroscopic control as shown in the cement injection movie cases . This combination has many advantages. The possibilities of the simultaneous combination of the two imaging methods are almost unlimited and other applications in interventional radiology are possible .

(go to movie page)



## Local anesthesia

The procedure is performed under local anesthesia usually combined with neuroleptanalgesia. The skin, subcutaneous layers, muscles and the periosteum are infiltrated by local anesthesia ( 1% lidocaine ) with a 22-gauge needle, 9 cm long.


Illustration is provided in the local anesthesia movie

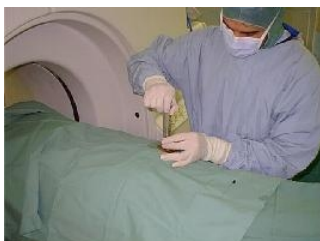

Fig 10: Local anesthesia

## Puncture

After positioning the patient, under neuroleptanalgesia and local anesthesia, a 10- to 15-gauge trocar needle is introduced into the vertebral body. Different approach routes can be selected : the anterior route for cervical level, the transpedicular and intercostovertebral route for the thoracic level, the transpedicular route for the lumbar level.

(illustration is provided in the puncture movie cases).

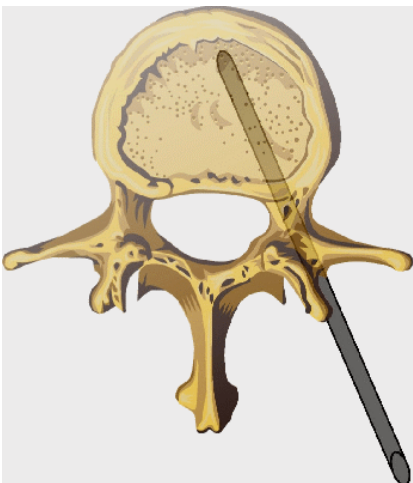


Fig 11: Transpedicular

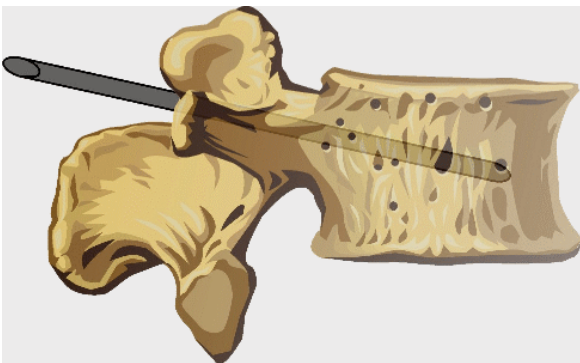


Fig 12: Transpedicular route

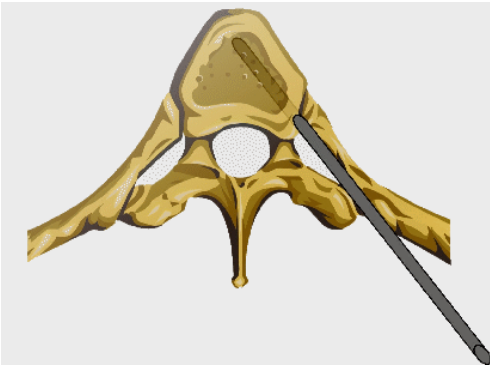


Fig 13: Intercostovertebral route

The needle is guided safely under CT. Precise controlled cortical perforation requires the aid of a surgical hammer. When the needle is in the optimal position (needle tip in the anterior third of the vertebral body), the imaging mode is switched to fluoroscopy (illustration is provided in the puncture movie cases ).

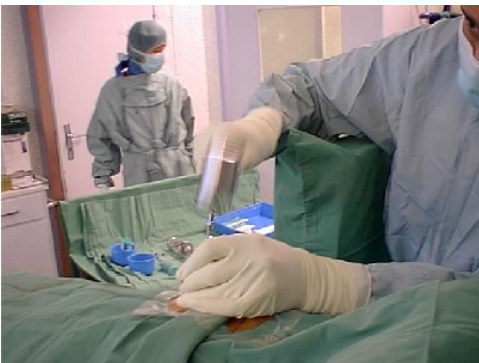

Fig 14: puncture

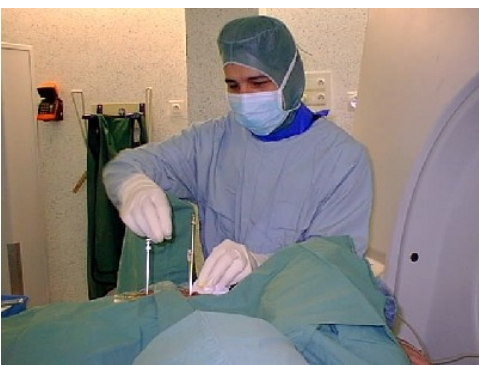

Fig 15: surgical hammer



## Puncture demonstration

illustration is provided in the puncture movie [cases](#)

## Preparation of the cement

A package of methyl methacrylate (Howmedica®, Microlok®, Palacos or Simplex®) low viscosity is composed of a packet of 20 g powder and a tube of 20 ml fluid monomer. The acrylic glue is prepared by mixing 20 g of powder and 20 ml of fluid monomer. Then half of the glue is discarded and because the cement is not sufficiently radiopaque, 3 g of tantalum is added to the mixture. Illustration is provided in the cement preparation movie [cases](#)

Illustration is provided in the cement preparation movie [cases](#)

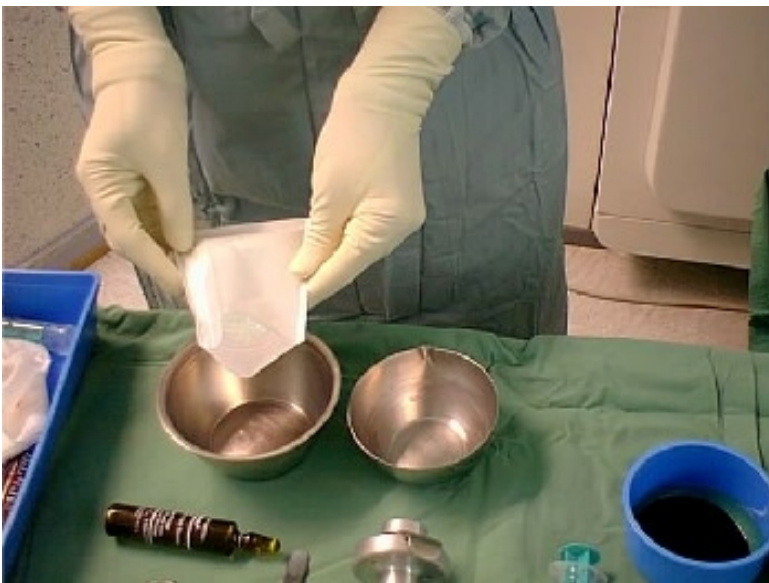

Fig 16: PMM powder + monomer

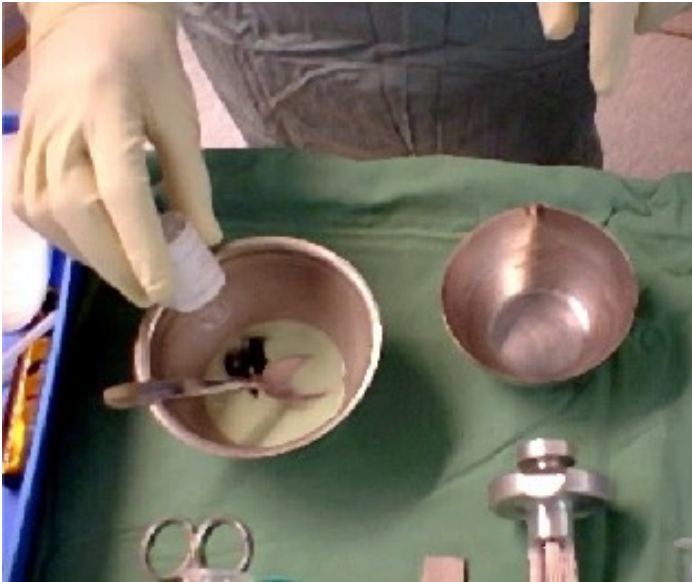

Fig 17: PMM + tantalum powder

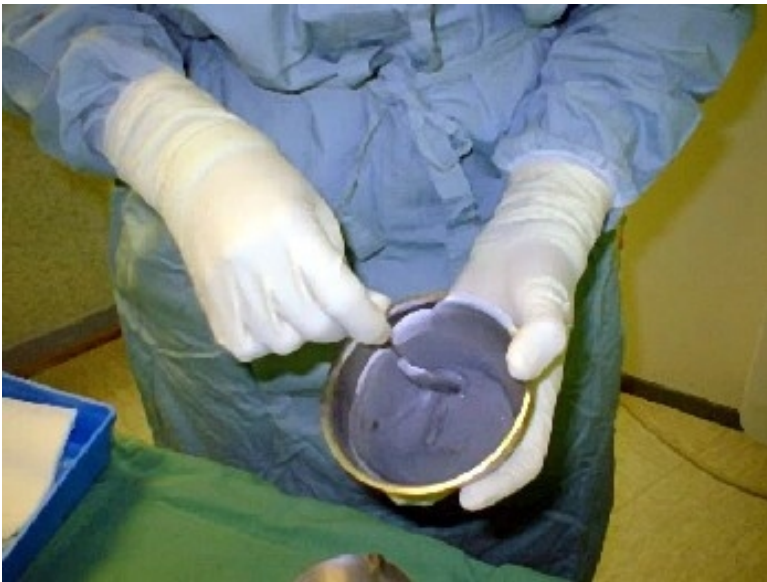

Fig 18: End product after mixing

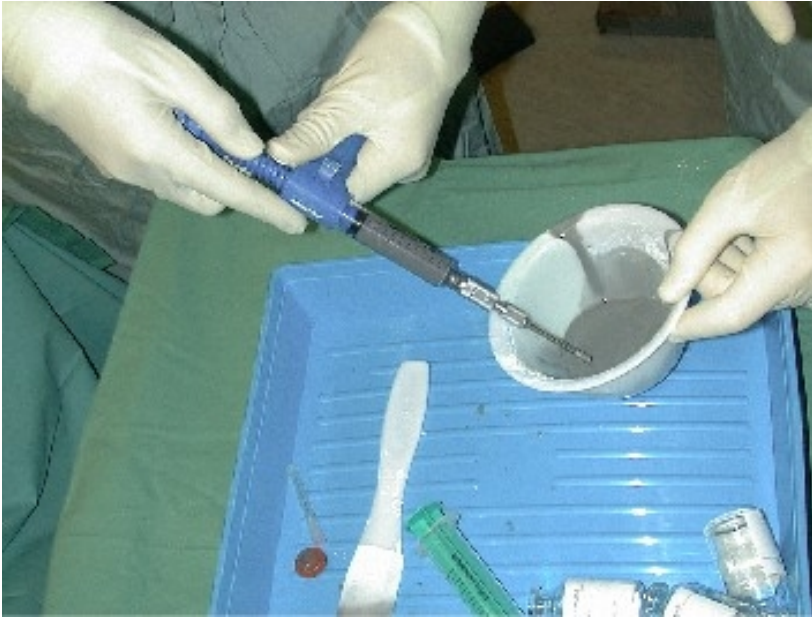

Fig 19: Syringe filling

During the first 30-50 seconds after mixing, the glue is thin but then becomes pasty. The acrylic cement has to be injected during its pasty polymerization phase to prevent distal venous migration. Between two to eight milliliters of acrylic glue are injected using a pressure syringe (Optimed®) to facilitate the injection of this viscous mixture. This stage of the procedure must be performed quickly because the glue begins to thicken after three minutes and any further injections become impossible.

### **Injection of the cement**

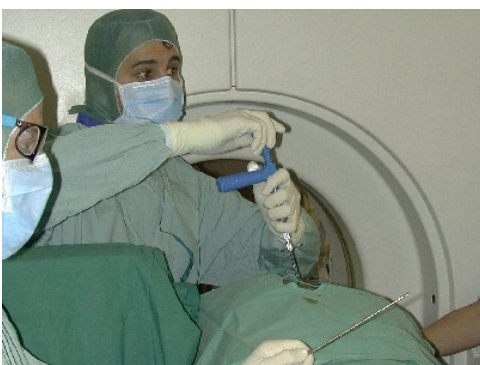

Fig 20: Injection of the cement

This phase of the procedure is controlled under strict lateral fluoroscopy. The injection of acrylic glue is stopped immediately whenever an epidural or paravertebral opacification is observed in order to prevent spinal cord compression. When vertebral filling is insufficient, a contra-lateral injection is suggested in order to complete the filling. After the vertebral filling, the mandrin of the needle is replaced again under fluoroscopic control before the cement begins to set (because the needle itself contains about 1 ml glue). Then the needle is removed carefully. Six to seven minutes after mixing, the methyl methacrylate begins to harden. During this hardening time, the methyl methacrylate becomes hot (+/- 90 °C). The patient should be under neureuleptanalgesia to control pain. Monitoring of the arterial pressure is necessary during the procedure because methyl methacrylate injections can induce transient hypotension. Total procedure time ranges from 20 to 50 minutes. In patients with osteoporosis and symptomatic hemangioma, an optimal filling (2.5 - 4 ml) of the vertebral body is required to obtain both effects of percutaneous vertebroplasty : consolidation and pain relief. In patients with tumoral pathologies, percutaneous cementoplasty is usually performed for excruciating pain. In these cases, a low volume (1.5 - 2.5 ml) of acrylic glue provides good pain relief. Illustration is provided in the cement injection movie cases

Illustration is provided in the cement injection movie cases

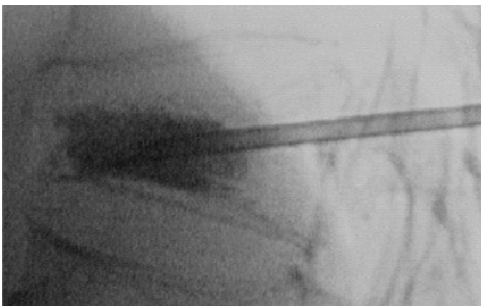

Fig 21: Injection of the cement under fluoroscopy

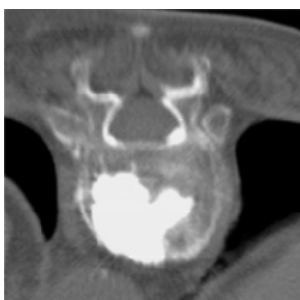
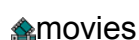
Fig 22: CT control

## 6) Demonstration movies

Illustration is provided in Demonstration



movies

## 7) Complications

- The major complications are cement leaks.
- The second complication is infection. To avoid this complication, strict sterility during the intervention is mandatory.
- Temporary pain can be observed after the procedure. The patients are usually free of symptoms after 24 hours. Post-procedural pain is usually proportional to the volume of glue injected. The majority of these patients had good packing of the vertebral body with more than 4 ml of acrylic glue injected.
- The risk of allergic accidents and hypertension is limited in these procedures, because the quantities of acrylic glue injected in percutaneous cementoplasty are far less than those used in orthopedic surgery.

## 8) Results

### Results Overview

From 1990 to 1999 we performed percutaneous cementoplasty in 187 patients : indications included severe painful osteoporosis (105 patients), vertebral tumors (myeloma and metastasis 69 patients), symptomatic hemangiomas (11 patients), and postchirurgical decompression (2 patients). A total of 289 vertebral bodies were injected ( mean of 1.54 vertebra/patient). The average volume of cement injected was 2.8 ml (ranging from 1.8 to 6.5 ml). The analgesic effect appeared within 12 to 48 hours after procedure. The results were evaluated according to the reduction of opiate analgesic doses. Satisfactory results (pain score > 2) were obtained in 79% of the patients . An analgesic score of 3 or higher was achieved in 71% of the patients. Percutaneous cementoplasty is a successful technique for pain management and consolidation of pathologic vertebral bodies. The most critical elements for successful vertebroplasty are proper patient selection, correct needle placement, good timing of cement injection, strict fluoroscopy control of injection, and operator's experience. The good pain relief obtained with this technique is not correlated with the volume of glue injected, especially in metastasis where 1.5 ml of glue is usually enough to reduce considerably the patient's pain.

### ANALGESIC SCORE DEFINITION

Score	Definition
1	little or no relief
2	moderate relief ( 25% to 50% reduction of analgesic doses)
3	very good but incomplete relief (75% reduction of analgesic doses)
4	complete relief

### Detailed Results

Score	Number of patients	%
greater than or equal to 2	82	78

### OSTEOPOROSIS (105 CASES)

Satisfactory results were obtained in 78% of the cases based on the reduction of analgesics doses. Maximum follow-up was 7 years (average 2,7 years).

Score	Number of patients	%
greater than or equal to 2	57	83

### VERTEBRAL TUMORS (69 CASES)

Satisfactory results were obtained in 85% of the cases based on the reduction of opiate doses. Maximum follow-up was 1,2 years (average 7 months).

Score	Number of patients	%
greater than or equal to 2	8	73

### HEMANGIOMAS (11 CASES)

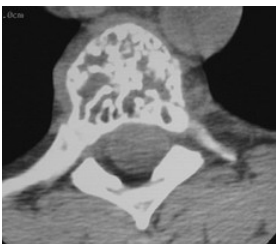
Satisfactory results were obtained in 78 % of the cases based on the reduction of opiate doses. Maximum follow-up was 6 years (average 3,8 years).

In 3 cases with epidural extension with neurologic complications, first percutaneous vertebroplasty was performed and the surgical intervention was carried out for epidural decompression in a second phase.

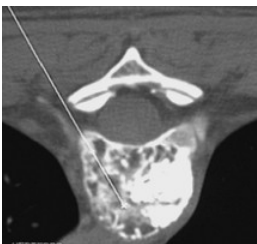
## 9) Cases

**Case 1 : Percutaneous cementoplasty. intercostovertebral route.**

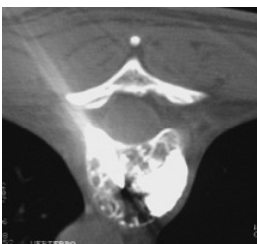**Indication: aggressive vertebral angioma. Bilateral approach. No complications.**



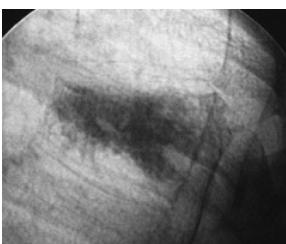
CT : Vertebral angioma



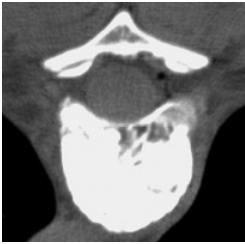PC : CT pathway



PC : Puncture CT control

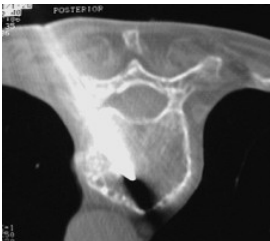

PC : Fluoroscopy control

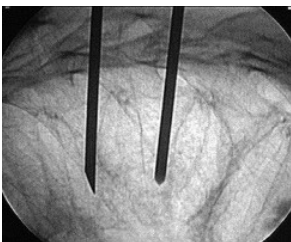


PC : CT control

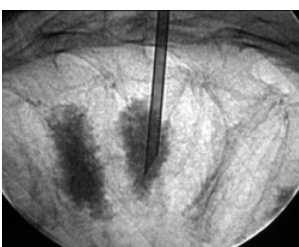**Case 2 : Percutaneous cementoplasty at five levels. Intercostovertebral route. Indication : severe osteoporosis with loss of height and with several compression fractures of vertebral bodies. No complications**



PC : Puncture CT control

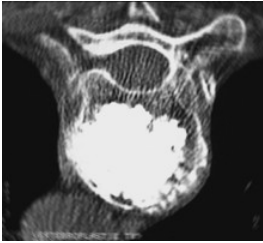


PC : Puncture fluoroscopy control

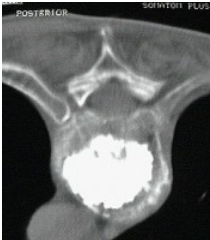

PC : Cement injection fluoroscopy control

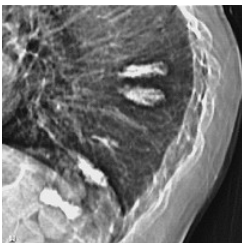



PC : CT control

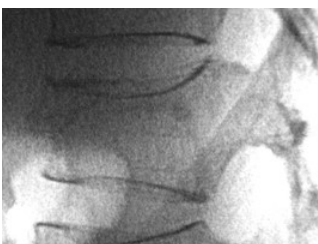

PC : CT control

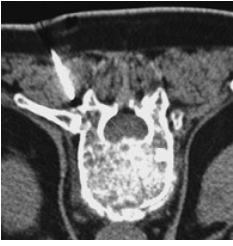

PC : Fluoroscopy control

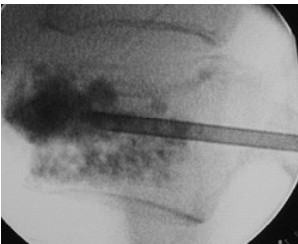
**Case 3 : Percutaneous cementoplasty. I ntercostovertebral route.  
Indication : severe osteoporosis. No complications**



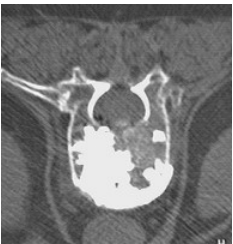
Fluoroscopy : severe osteoporosis



PC : vertebral puncture CT control

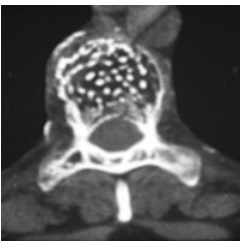


PC : Cement injection fluoroscopy control

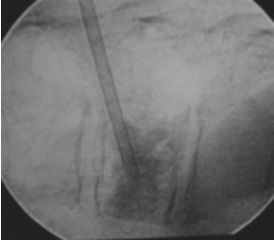


PC : CT control

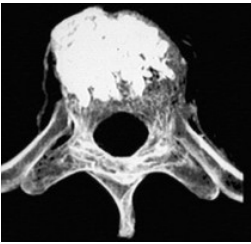
**Case 4 : Percutaneous cementoplasty. Transpedicular route. Indication : vertebral angioma**



CT vertebral angioma

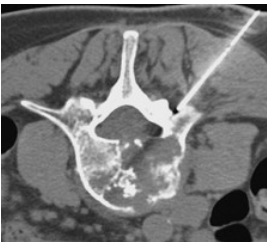


PC: Cement injection fluoroscopy control

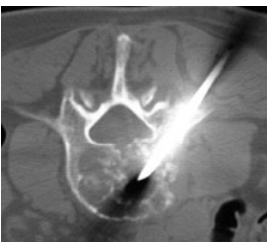

PC : CT 3D reconstruction

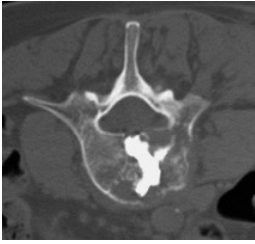
**Case 5 : Percutaneous cementoplasty : injection of 3.5 ml of glue.  
Transpedicular route. Indication : painful metastases. Good pain relief,  
no complications.**



PC : Local anesthesia CT control

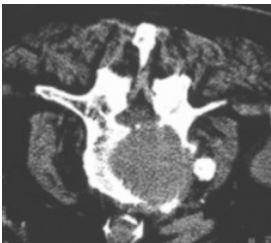

PC : Puncture CT control

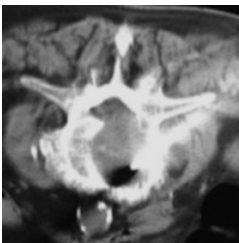


PC : CT control

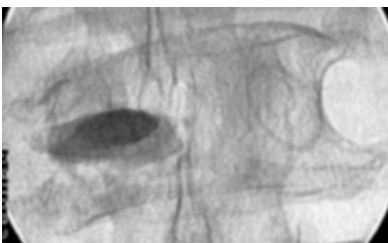
**Case 6 Vertebroplasty : injection of 2.5 ml of glue. Posterolateral route.  
Indication : painful metastases. No complications.**



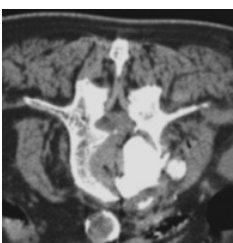
CT Osteolytic metastasis



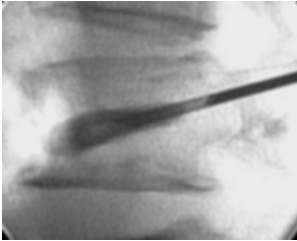
PC : Puncture CT control



PC: Cement injection fluoroscopy control

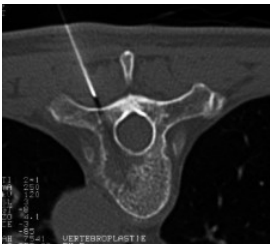

PC : CT control

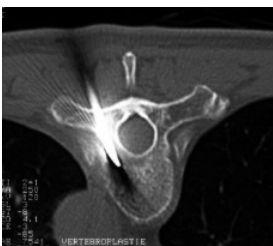

PC: Cement injection fluoroscopy control

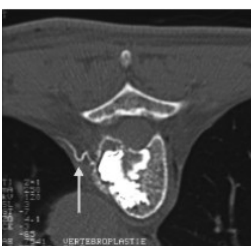
**Case 7 : Percutaneous cementoplasty. Transpedicular route. Indications : osteolytic hypervascular breast cancer metastasis. Cement leak in the intercostal artery**



PC : Local anesthesia CT control

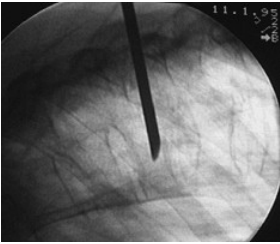


PC : Puncture CT control

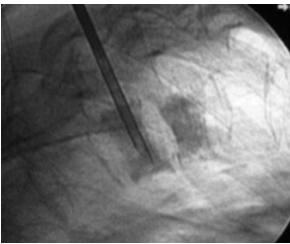


PC : CT control, intercostal artery leak ( arrow )

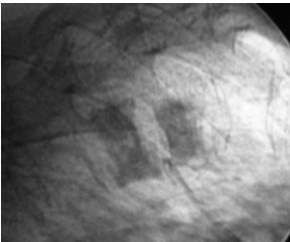
**Case 8 : Percutaneous cementoplasty at two levels. Intercostovertebral route. Indication : severe osteoporosis. Minimal venous leak**



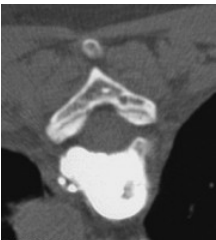PC : Puncture fluoroscopy control



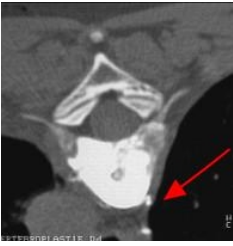PC : Cement injection under fluoroscopy



PC : Fluoroscopy control

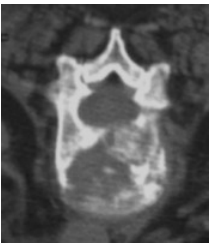


PC : CT control venous leak

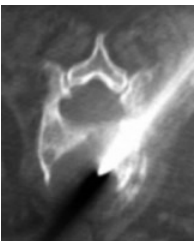

PC : CT control minimal

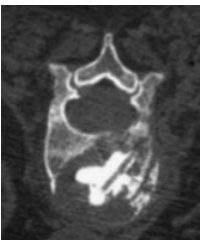**Case 9 Percutaneous cementoplasty : injection of 3.5 ml of glue. Intercostovertebral route. Indication : painful metastases. Good pain relief, no complications.**



CT osteolytic metastasis

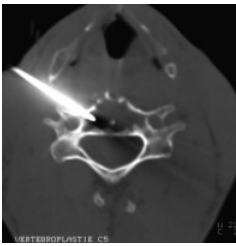


PC : Puncture CT control

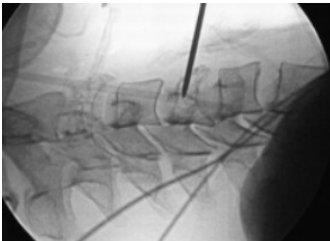


PC : CT control

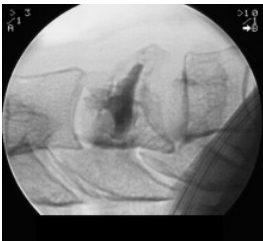
**Case 10 : Percutaneous cementoplasty at C4 level, anterior route.  
Indication : myeloma. Minimal discal leak C3-C4**



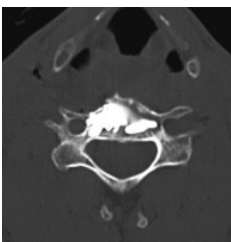
PC : Puncture CT control



PC : Puncture fluoroscopy control



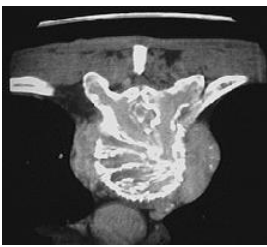
PC : Fluoroscopy control, discal leak



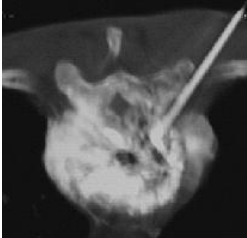
PC : CT control

Case 11 Percutaneous cementoplasty. Indication : aggressive vertebral angioma.  
Intercostovertebral pathway. First percutaneous vertebroplasty was performed and the surgical intervention was carried out for epidural decompression in a second phase.

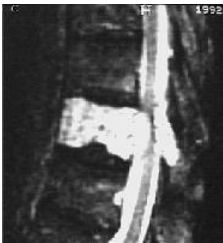



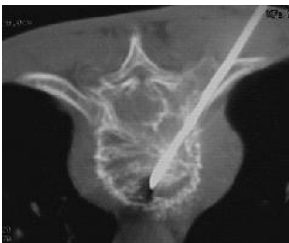CT : aggressive angioma



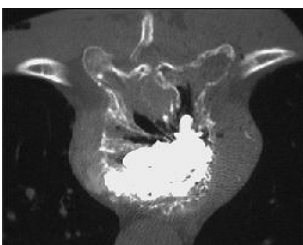
CT : venography



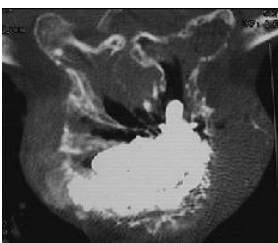
MRI : aggressive angioma with spinal cord compression



CT : aggressive angioma, puncture

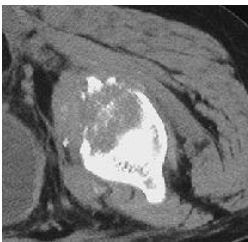


PC : CT control

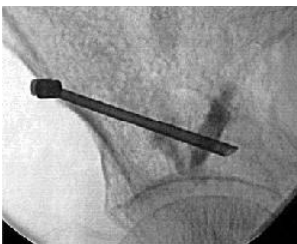

PC : CT control

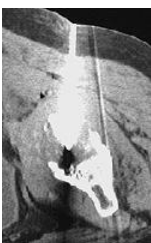Case 12 : Percutaneous acetabular cementoplasty. Same technique as vertebroplasty.  
Indication : painful metastases. Good pain relief, no complications.



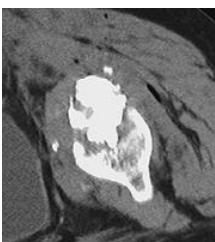
CT : osteolytic metastasis of acetabulum



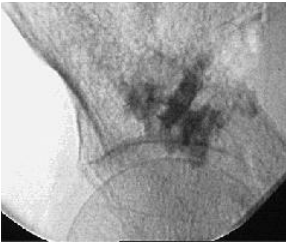Fluoroscopy : osteolytic metastasis of acetabulum



CT : acetabular cementoplasty

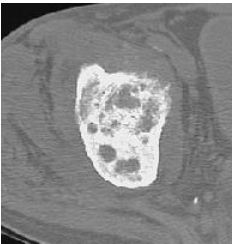


CT control : acetabular cementoplasty

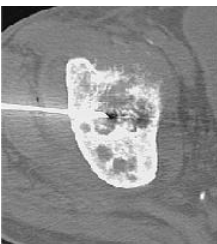


Fluoroscopy : acetabular cementoplasty

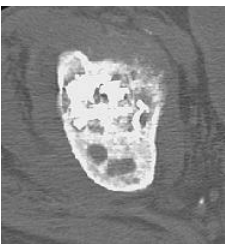
Case 13 : Percutaneous acetabular cementoplasty. Same technique as vertebroplasty.  
Indication : painful metastases. Good pain relief, no complications.



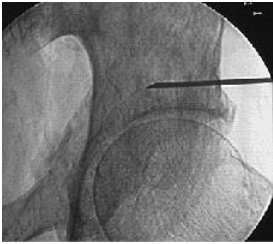
CT : osteolytic acetabular metastasis



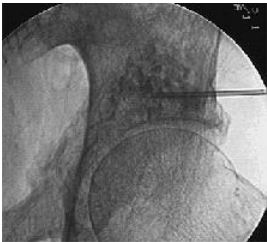
Puncture : CT control



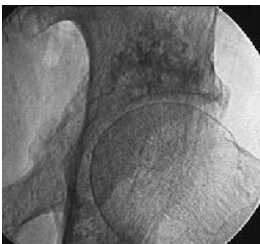Acetabular cementoplasty : CT control



Puncture : fluoroscopy control



Injection : fluoroscopy control



Acetabular cementoplasty : fluoroscopy control

## 10) BIBLIOGRAPHY

1	<a href="#"><u>Belkoff SM, Mathis JM, Jasper LE, Deramond H. The biomechanics of vertebroplasty. The effect of cement volume on mechanical behavior. Spine. 2001 Jul 15;26(14):1537-41.</u></a>
2	<a href="#"><u>Cotten A, Dewatre F, Cortet B et al. Percutaneous vertebroplasty for osteolytic metastases and myeloma: effects of the percentage of lesion filling and leakage of methyl methacrylate at clinical follow-up . Radiology 2000 : 525-530 , 1996</u></a>
3	<a href="#"><u>Cotten A, Boutry N, Cortet B, Assaker R, Demondion X, Leblond D, Chastanet P, Duquesnoy B, Deramond H. Percutaneous vertebroplasty: state of the art. Radiographics. 1998 Mar-Apr;18(2):311-20; discussion 320-3.</u></a>
4	<a href="#"><u>Deramond H, Depriester C, Toussaint P, Galibert P. Percutaneous Vertebroplasty. Semin Musculoskelet Radiol. 1997;1(2):285-296.</u></a>
5	<a href="#"><u>Deramond H, Wright NT, Belkoff SM. Temperature elevation caused by bone cement polymerization during vertebroplasty. Bone. 1999 Aug;25(2 Suppl):17S-21S.</u></a>
6	<a href="#"><u>Deramond H, Depriester C, Galibert P, Le Gars D. Percutaneous vertebroplasty with polymethylmethacrylate. Technique, indications, and results. Radiol Clin North Am. 1998 May;36(3):533-46.</u></a>
7	Deramond H La neuroradiologie interventionnelle . Bull Acad Natl Med 175 : 1103-1112 , 1991
8	<a href="#"><u>Deramond H, Depriester C, Galibert P, Le Gars D Percutaneous vertebroplasty with polymethacrylate : technique, indications, results . Radiol Clin North Am 3 : 533-547 , 1998</u></a>
9	Firooznia H, Rauschnig W, Rafii M, Golimbu C Normal correlative anatomy of the lumbosacral spine and its contents . Neuroimaging Clinics of North America 3 : 411-424 , 1993
10	Gangi A, Dietemann JL, Dondelinger RF Tomodensitométrie interventionnelle . Paris, Vigot : 233-246 , 1994
11	<a href="#"><u>Gangi A, Dietemann JL, Gasser B, Guth S, Unamuno S, Fogarassi E, Fuchs C, Sieffert P, Roy C Interventional radiology with laser in bone and joint . Radiol Clin North Am 3 : 547-559 , 1998</u></a>
12	Gangi A, Dietemann JL, Guth S, Steib JP, Roy C Computed tomography and fluoroscopy-guided vertebroplasty: Results and complications in 187 patients . Sem in Intervent Radiol 16-2 : 137-141 , 1999
13	<a href="#"><u>Gangi A, Dietemann JL, Schultz A, Mortazavi R, Jeung MY, Roy C Interventional radiologic procedures with CT guidance in cancer pain management . Radiographics 16 : 1289-1304 , 1996</u></a>
14	<a href="#"><u>Gangi A, Kastler B, Dietemann JL. Percutaneous vertebroplasty guided by a combination of CT and fluoroscopy . AJNR 15 : 83-86 , 1994</u></a>
15	Gangi A, Kastler B, Klinkert A, Dietemann JL Interventional radiology guided by a combination of CT and fluoroscopy : technique, indication and advantages . Sem in Intervent Radiol 12 : 4-14 , 1995
16	<a href="#"><u>Gangi A, Kastler B, Klinkert A, Dietemann JL Injection of alcohol into bone metastases under CT guidance. . Journal of Computed Assisted Tomography 18 : 932-935 , 1994</u></a>
17	<a href="#"><u>Grados F, Depriester C, Cayrolle G, Hardy N, Deramond H, Fardellone P. Long-term observations of vertebral osteoporotic fractures treated by percutaneous vertebroplasty.</u></a>

	<a href="#"><u>Rheumatology (Oxford). 2000 Dec;39(12):1410-4.</u></a>
18	<a href="#"><u>Ghelman B Biopsies of the musculoskeletal System . Radiol Clin North Am 3 : 567-581 , 1998</u></a>
19	<a href="#"><u>Harrington KD The use of methyl methacrylate for vertebral body replacement and anterior stabilization of pathological fracture dislocations of the spine due to metastatic malignant disease . J Bone Joint Surg 63 : 36-46 , 1981</u></a>
20	<a href="#"><u>Ide CH, Gangi A, Rimmelin A et al. Vertebral haemangioma with spinal cord compression: the place of preoperative percutaneous vertebroplasty . Neuroradiology 38 : 585-589 , 1996</u></a>
21	Jerosch J Minimal invasive Therapie des lumbalen Bandscheibenvorfalles . Die Medizinische Welt 44 : 255-262 , 1993
22	<a href="#"><u>Kaemmerlen P, Thiesse P, Bouvard H, Biron P, Mornex F, Jonas P Vertebroplastie percutanee dans le traitement des metastases . Technique et resultats . J Radiol 70 : 557-562 , 1989</u></a>
23	<a href="#"><u>Mathis JM, Barr JD, Belkoff SM, Barr MS, Jensen ME, Deramond H. Percutaneous vertebroplasty: a developing standard of care for vertebral compression fractures. AJNR Am J Neuroradiol. 2001 Feb;22(2):373-81.</u></a>
24	<a href="#"><u>Murphy KJ, Deramond H. Percutaneous vertebroplasty in benign and malignant disease. Neuroimaging Clin N Am. 2000 Aug;10(3):535-45.</u></a>
25	<a href="#"><u>Nielsen OS, Munro AJ, Tannock IF Bone metastases : Pathophysiology and managment policy . Journal of Clinical Oncology 3 : 509-524 , 1991</u></a>
26	Panjabi MM, Hopper W, White AA, Keggi KI Posterior spine stabilization with methyl methacrylate biomechanical testing of a surgical specimen . Spine 2 : 241-247 , 1977
27	<a href="#"><u>Rentfrew DL, Whitten CG, Wiese JA, El-khoury GY, Harris KG CT-guded percutaneous transpedicular biopsy of the spine . Radiology 180 : 574-576 , 1991</u></a>
28	Stoll BA, Parbhoo S Natural history, prognosis, and staging of bone metastases, in Bone metastases: Monitoring and treatment . New York, NY, Raven : 1-20 , 1983
29	<a href="#"><u>Tong D, Gillick L, Hendrickson FR. The palliation of symptomatic osseous metastases : Final results of the study by the radiation therapy oncology group . Cancer 50 : 893 , 1982</u></a>
30	<a href="#"><u>Vecht CJ, Hoff AM, Kansen PJ, de Boer MF, Bosch DA Types and causes of pain in cancer of the head and neck . Cancer 70 : 178-184 , 1992</u></a>
31	<a href="#"><u>Weill A, Chiras J, Simon JM, Rose M, Rola-Martinez T, Enkouala E Spinal metastasis : indication for and results of percutaneous injection of acrylic surgical cement . Radiology 36 : 533-546 , 1996</u></a>